

# Indications and Outcomes for Surgical Treatment of Patients with Chronic Migraine Headaches Caused by Occipital Neuralgia

Ivica Ducic, M.D., Ph.D.  
Emily C. Hartmann, M.D.  
Ethan E. Larson, M.D.  
Washington, D.C.

**Background:** Occipital neuralgia is a headache syndrome characterized by paroxysmal headaches localizing to the posterior scalp. The critical diagnostic feature is symptomatic response to local anesthetic blockade of the greater or lesser occipital nerve. Further characterization is debated in the literature regarding the diagnosis and optimal management of this condition. The authors present the largest reported series of surgical neurolysis of the greater occipital nerve in the management of occipital neuralgia.

**Methods:** A retrospective chart review was conducted to identify 206 consecutive patients undergoing neurolysis of the greater or, less commonly, excision of the greater and/or lesser occipital nerves. A detailed description of the procedure is presented, as is the algorithm for patient selection and timing of surgery. Preoperative and postoperative visual analogue pain scores and migraine headache indices were measured. Success was defined as a reduction in pain of 50 percent or greater.

**Results:** Of 206 patients, 190 underwent greater occipital nerve neurolysis (171 bilateral). Twelve patients underwent greater and lesser occipital nerve excision, whereas four underwent lesser occipital nerve excision alone. The authors found that 80.5 percent of patients experienced at least 50 percent pain relief and 43.4 percent of patients experienced complete relief of headache. Mean preoperative pain score was  $7.9 \pm 1.4$ . Mean postoperative pain was  $1.9 \pm 1.8$ . Minimum duration of follow-up was 12 months. There were two minor complications.

**Conclusion:** Neurolysis of the greater occipital nerve appears to provide safe, durable pain relief in the majority of selected patients with chronic headaches caused by occipital neuralgia. (*Plast. Reconstr. Surg.* 123: 1453, 2009.)

Occipital neuralgia is a refractory and disabling disorder characterized by recurrent headaches of moderate to severe intensity localized to the occipital region, with occasional radiation to the neck and face. Many patients suffer for years. This translates into diminished productivity, dependence on pain medications, and frustration on the part of the patient and practitioner. Described in 1821,<sup>1</sup> numerous causes have been theorized and a variety of interventions used in the treatment of occipital neuralgia. Currently,

there is no clear consensus on diagnosis and management.<sup>2</sup>

The nomenclature can be confusing. There are over 180 types of headache recognized by the International Headache Society.<sup>3</sup> Occipital neuralgia is a subset, existing along a continuum of posttraumatic pain, whiplash, cervical spine abnormality, tension headache, chronic daily headache, and migraine. Monikers applied have included Arnold neuralgia, syndrome sympathique cervicale posterieur,<sup>4,5</sup> migraine cervicale, occipital neuritis,<sup>4</sup> cervicogenic headache,<sup>5</sup> and spinally transformed migraine.<sup>6</sup> Although there is little agreement on diagnostic criteria, the pertinent

*From the Department of Plastic Surgery, Georgetown University.*

*Received for publication August 27, 2008; accepted November 11, 2008.*

*Presented at the IVth Congress of the World Society for Reconstructive Microsurgery, in Athens, Greece, June 24 through 26, 2007.*

*Copyright ©2009 by the American Society of Plastic Surgeons*

DOI: 10.1097/PRS.0b013e3181a0720e

**Disclosure:** None of the authors has a financial interest in any of the products mentioned in this article.

findings tend to be tenderness over the occipital nerves and headache elimination by anesthetic block of the occipital nerve on the affected side(s).

Various treatment modalities have been used. These include nerve stimulators,<sup>6–8</sup> C2 gangliotomy,<sup>9</sup> C2 gangliectomy,<sup>10</sup> C2 to C3 rhizotomy,<sup>11</sup> C2 to C3 root decompression,<sup>12</sup> radiofrequency lesioning,<sup>13</sup> subdermal denervation,<sup>14</sup> neurectomy,<sup>15</sup> and neurolysis with or without section of the inferior oblique muscle.<sup>16–19</sup> These have enjoyed varying degrees of success and often suffer from a limited sample size. We report a series of 206 patients treated for occipital neuralgia with surgical neurolysis of the greater occipital nerve or excision of the lesser occipital nerve.

### PATIENTS AND METHODS

After institutional review board approval, a retrospective chart review was conducted of 206 consecutive patients presenting to the senior author (I.D.) with occipital neuralgia between February of 2005 and June of 2007 undergoing surgical treatment for occipital neuralgia.

There were 38 men and 168 women (18.4 percent and 81.6 percent, respectively). Average age of the patients was 45 years. Headaches were typically bilateral (171 of 206). Average years with headache was 17 (range, 0.6 to 60 years). Ninety-two percent of patients demonstrated tenderness over the greater occipital nerve on examination, with 90 percent responding to nerve block [2 ml of 0.5% bupivacaine with 0.5 ml of 40 mg Kenalog (Bristol-Myers Squibb, New York, N.Y.)]. Twenty patients had been treated with Botox (Allergan, Inc., Irvine, Calif.), with 17 (85 percent) demonstrating an interval of improvement (Table 1).

Pain was typically stabbing/lancinating in character, originating at the occiput and radiating over the posterior scalp and occasionally temple or face. Often, diminished sensation or dysesthesia was present, and pressure over the greater occipital nerve could recreate symptoms. Patients occasionally reported pain with hyperextension or rotation of the neck, preventing some from lying on a pillow (“pillow sign”).

All patients had a workup performed by a neurologist before treatment to rule out other causes. No patients were treated surgically unless they had had symptoms for 6 months or longer. Nerve blocks were performed 2 to 3 cm inferior to the occipital protuberance and 2 cm lateral to the midline. All patients had attempted other treatment modalities, including pharmacotherapy, anesthetic and steroid injection, Botox, acupuncture, and electrostimulation, with limited success.

**Table 1. Preoperative Characteristics of Patients with Occipital Neuralgia Chronic Headaches**

	Value (%)
No. of patients	206
Sex	
Male	38 (18.4)
Female	168 (81.6)
Age (yr)	45 ± 2.9
Headache laterality	
Bilateral	171
Unilateral	35
No. of years with headache	
Average	17 ± 9.3
Range	0.6–60
Preoperative VAS score for pain	
Average	7.9 ± 1.4
Range	4–10
Migraine headache index (preoperatively)*	287 ± 14.9
GON/LON tenderness at initial examination	190/206 (92.20)
GON/LON nerve block (effective)	186/206 (90.20)
Botox (effective)	17/20 (8)

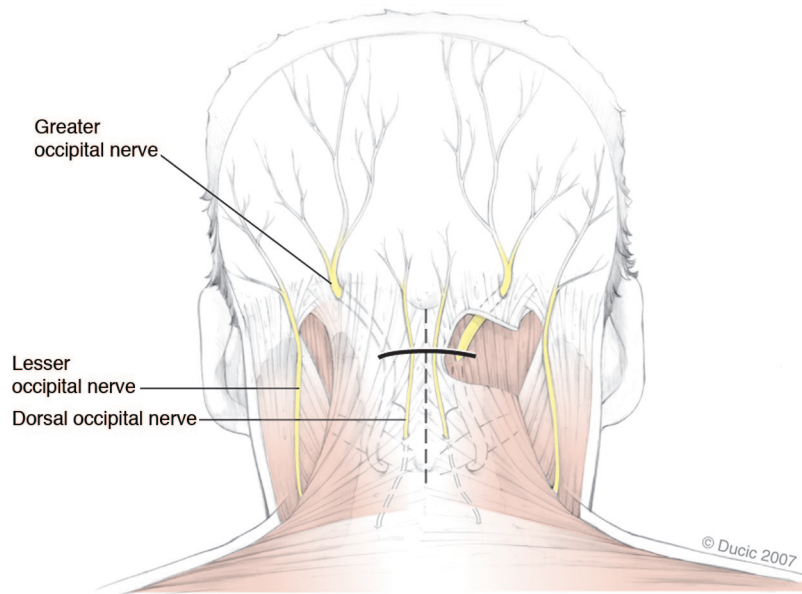
VAS, visual analogue scale; GON, greater occipital nerve; LON, lesser occipital nerve.

\*Days/months × intensity (0–10) × duration (fraction of 24 hr).

Pain was assessed using a visual analogue scale from 0 to 10, with 0 being no pain and 10 being the worst pain imaginable. Minimum follow-up was 12 months. At follow-up, all patients were interviewed independently by a medical student with a standard questionnaire. Preoperative/postoperative pain levels were compared. The migraine headache index was measured as well [days/months × intensity (0–10) × duration (fraction of 24 hours)]. The results were compared statistically using Wilcoxon signed rank and Fisher’s exact tests ( $p < 0.05$  indicates statistical significance). Therapeutic success was defined as a reduction of pain by at least 50 percent.

### Surgical Technique

The midline of the neck and posterior scalp is marked and the horizontal incision is drawn approximately 3 cm below the occipital protuberance. With the patient prone, under general anesthesia, a horizontal 5- to 6-cm incision is made along this line as shown in Figure 1. The head is not shaved; rather, a comb and tape are used to retract the hair. The incision is deepened in anatomical planes to expose the trapezius. A vertical incision is developed over the trapezius fascia where 1 to 3 mm of vertically oriented muscle fibers are present. If a small branch of the dorsal occipital nerve is identified within the field, it can be resected under tension and allowed to retract into the musculature so that it would not become entrapped by scar within the dissection field, causing a painful neuroma. Careful dissection is then



**Fig. 1.** Recommended incision to access bilateral greater occipital nerves.

used within the vertical incision to identify the greater occipital nerve, typically as it emerges from the semispinalis capitis muscle. Similar to the published report, a dissection is first carried proximally, removing the small medial piece of the semispinalis capitis muscle abutting the greater occipital nerve, and then inferiorly to release the obliquus capitis muscle fibers overlying the greater occipital nerve.<sup>19</sup> In approximately 6 percent of patients, the nerve is found to be split within the substance of the semispinalis capitis muscle. In this case, the muscle fibers splitting the nerve are also released. Dissection is carried distally, releasing the nerve within the trapezial tunnel (the site where the greater occipital nerve penetrates through the trapezial fascial attachments to the occiput). This 1- to 2-cm tunnel has an oblique superolateral direction and often contains angiolymphatics, another possible compression variable to be acknowledged.<sup>4</sup> Usually, at its superolateral distal end, the occipital artery and vein cross the greater occipital nerve. If the vessel is found to impinge the nerve, it is dissected free and ligated. Enlarged and abutting lymph nodes are also removed from the tunnel, further decompressing the nerve. The same incision is used to treat the opposite side when needed. The wound is closed in anatomical layers without drains.

If unilateral lesser occipital nerve excision is performed concurrently, a 3-cm incision is made at a separate site lateral to the first incision, over the path of the lesser occipital nerve, which is identified along the posterior sternocleidomastoid at its middle third. The lesser occipital nerve can be de-

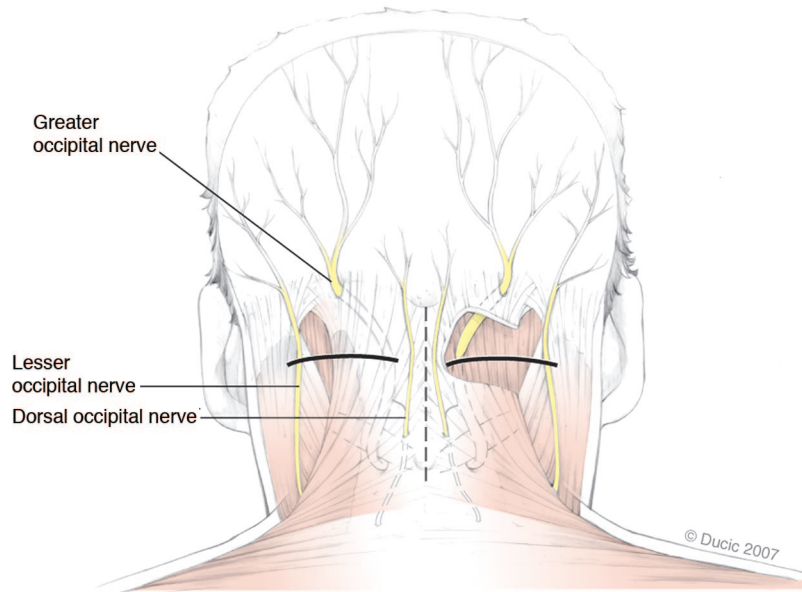
compressed or excised and its proximal stump implanted into muscle.

If bilateral greater occipital nerve decompression and lesser occipital nerve excision are performed, a modified approach is used. Two separate incisions are made, one on each side, each to access the ipsilateral greater occipital nerve and the lesser occipital nerve. In this way, not four but two incisions are made to access all nerves (Fig. 2). The entire, usually outpatient, procedure takes approximately 1 hour.

## RESULTS

Of 206 patients, 190 (92 percent) underwent greater occipital nerve neurolysis alone. Twelve (6 percent) underwent greater and lesser occipital nerve excision, and four patients (2 percent) had lesser occipital nerve excision alone. Average preoperative visual analogue scale score was  $7.9 \pm 1.4$  (range, 4 to 10). Average migraine headache index preoperatively was  $287 \pm 14.9$ .

Postoperative average visual analogue scale score was  $1.9 \pm 1.8$  (range, 0 to 8), a reduction of 6 (76 percent) ( $p < 0.0001$ ). Postoperative migraine headache index was  $24 \pm 11.8$  ( $p < 0.0001$ ). One hundred sixty-six patients (80.5 percent) had greater than 50 percent relief of pain. Seventy-two patients had complete relief (43.4 percent). Relief less than 50 percent was experienced by 40 patients (19.5 percent). There were two complications, both incisional cellulitis, that resolved with oral antibiotics (Table 2).



**Fig. 2.** Recommended incisions to access the greater and lesser occipital nerves bilaterally.

**Table 2. Postoperative Characteristics and Data for Patients with Occipital Neuralgia Chronic Headache**

	Value (%)
GON neurolysis	190/206 (92)
GON plus LON excision	12/206 (6)
LON excision	4/206 (2)
Postoperative VAS headache pain	
Average	1.9 ± 1.8
Range	0–8
Migraine headache index (postoperatively)*	24 ± 11.8
Outcome (same numbers stand for QOL improvement)	
Positive (>50% relief)	166/206 (80.5)
Complete ON headache relief	72/166 (43.4)
Failure (no relief, or <50%)	40/206 (19.5)
Complications	2/206 (incision cellulitis) (0.009)
Outpatient surgery	201/206 (97)

GON, greater occipital nerve; LON, lesser occipital nerve; VAS, visual analogue scale; QOL, quality of life; ON, occipital neuralgia.

\*Days/mo × intensity (0–10) × duration (fraction of 24 hr).

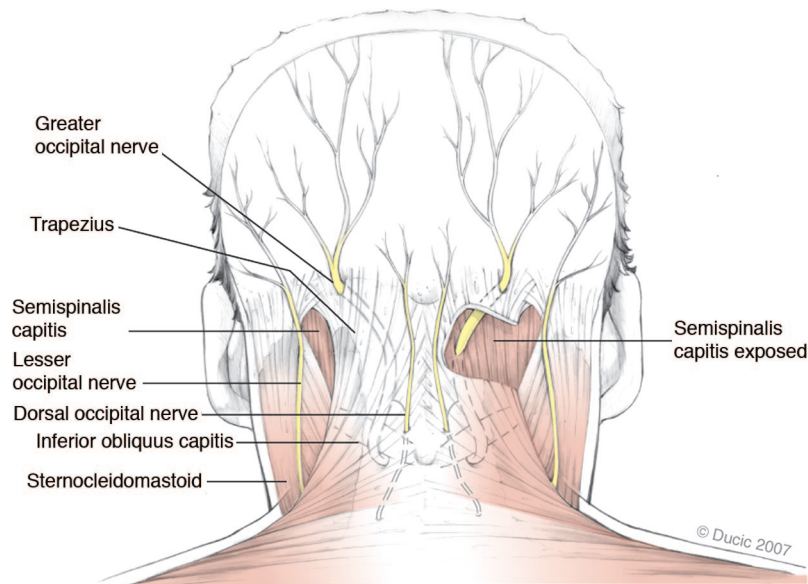
Factors correlated with a positive outcome included tenderness over the greater occipital nerve, positive response to greater occipital nerve block or Botox, a history of direct occipital trauma, and being under the care of a neurologist or pain specialist preoperatively. Negative outcomes were associated with a lack of greater occipital nerve tenderness, poor response to nerve block, mental illness, presence of other headache syndromes in addition to occipital neuralgia, or absence of concomitant treatment by a headache specialist.

## DISCUSSION

The greater occipital nerve has been described as the largest purely sensory nerve in the body.<sup>20</sup> It arises from the dorsal ramus of C2 deep to the inferior oblique muscle where it branches. The medial branch is the greater occipital nerve, which runs transversely along the inferior oblique and is covered by the splenius capitis, the longissimus, and the semispinalis muscles. Occasionally, the nerve travels within the substance of the inferior oblique muscle.<sup>21</sup> The nerve then turns upward to pierce the semispinalis capitis. Here, the nerve runs rostrally before emerging into the scalp by piercing the aponeurotic fibrous attachment of the trapezius and sternocleidomastoid to the superior nuchal line. In this aperture, the occipital artery and greater occipital nerve are in intimate association. Immediately below the superior nuchal line, the nerve divides into several terminal branches; medial branches innervate occipital skin and the lateral branches pass into the region behind the pinna<sup>22</sup> (Fig. 3).

It has been demonstrated that the greater occipital nerve most commonly emerges from the semispinalis muscle at a point 3 cm below the occipital protuberance and 1.5 cm lateral to the midline.<sup>21,23</sup> There are occasionally variations in this anatomy, particularly in the vertical axis.<sup>24,25</sup> It has been postulated that the C2 ramus could be compressed between the posterior arch of the atlas and the lamina of the axis; however, it has been





**Fig. 3.** Anatomy of the greater and lesser occipital nerves.

demonstrated that this nerve is not especially vulnerable at this location.<sup>22,26</sup>

The lesser occipital nerve arises from the dorsal rami of C2 and occasionally C3. It ascends toward the occiput parallel to the posterior border of the sternocleidomastoid muscle. Near the cranium, it perforates the deep fascia and continues superiorly over the occiput, where it innervates the skin and communicates medially with the greater occipital nerve.<sup>27</sup> There is some variability in anatomy, but the nerve tends to emerge from the posterior border of the sternocleidomastoid muscle above the point of emergence of the great auricular nerve. This point is approximately 60 to 70 mm from the midline and 40 to 60 mm inferior to a line drawn between the lowest points of the external auditory canals.<sup>23</sup> Occasionally, the nerve pierces the sternocleidomastoid.

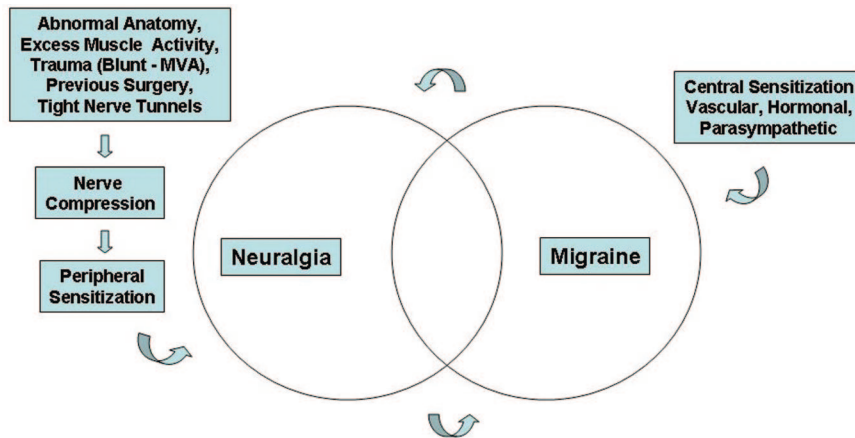
The diagnosis of occipital neuralgia can be difficult. There is overlap with other disorders, including cluster headache, paroxysmal hemicrania, tension headache, and migraine, and multiple types may be present in a given patient.<sup>32</sup> Prevalence is difficult to determine but has been found to range from 0.7 to 13 percent in headache patients.<sup>2</sup> Occipital neuralgia is described by the International Headache Society as a paroxysmal jabbing pain in the distribution of the greater or lesser occipital nerve accompanied by diminished sensation or dysesthesia. The most agreed on criteria for diagnosis include pain in the distribution of the greater or lesser occipital nerve; a stabbing, paroxysmal pain that may ache in be-

tween paroxysms; a nerve that is tender to palpation; and the fact that the condition can be relieved by injection of local anesthetic.<sup>28</sup> Occipital neuralgia may present with other symptoms, including nausea, tinnitus, dizziness, and visual disturbance, symptoms that overlap with migraine and cluster headache.<sup>29,30,31</sup>

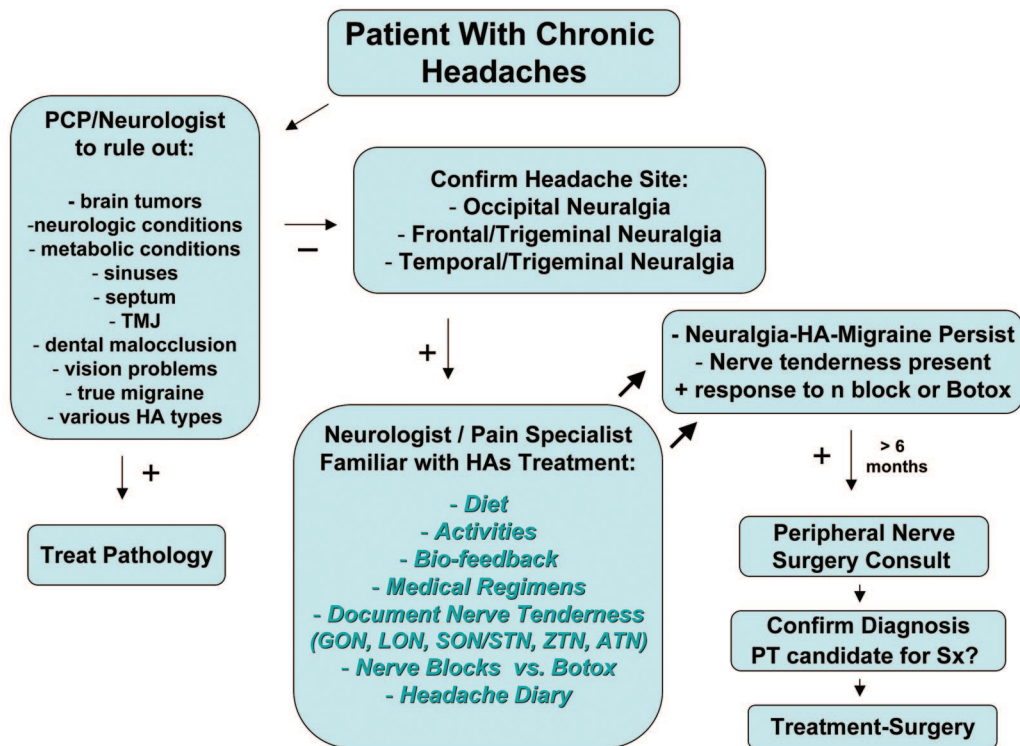
Given the lack of diagnostic consensus, it becomes difficult to interpret the literature with regard to efficacy of various treatments. It seems increasingly apparent that these disorders exist along a continuum of headache pain that is likely multifactorial and interrelated (Fig. 4).

In light of this, we selected specific inclusion criteria for consideration for surgery. As the cardinal feature of occipital neuralgia appears to be response to anesthetic blockade of the greater or lesser occipital nerve, we decided to operate only on patients who responded to this. If nerve block is ineffective, it can be repeated after 3 weeks at an adjacent site to overcome anatomical variation. Injection has not been shown to affect other headache types.<sup>32</sup> Similarly, a positive response to Botox injection was considered an indication for surgery. Tenderness over the greater occipital nerve or a positive Tinel sign were also included. Our algorithm is presented in Figure 5.

Occipital pain can arise from other conditions. These include Arnold-Chiari malformation, tumors, vertebrobasilar insufficiency, meningitis, arthritis, gout, polyneuropathy, syphilis, malaria, torticollis, myositis, mastoiditis, herpetic neuralgia, upper respiratory infection, and temporal



**Fig. 4.** Causative factors and overlap of headache pain syndromes. *MVA*, motor vehicle accident.



**Fig. 5.** Algorithm for management of occipital neuralgia. *PCP*, primary care physician; *TMJ*, temporomandibular joint; *HA*, headache; *PT*, patient; *Sx*, surgery; *GON*, greater occipital nerve; *LON*, lesser occipital nerve; *SON*, supraorbital nerve; *STN*, supratrochlear nerve; *ZTN*, zygomaticotemporal nerve; *ATN*, auriculotemporal nerve.

arteritis.<sup>12,26,33,34</sup> For this reason, neurologic consultation is recommended.

Various treatment modalities have been used in the treatment of occipital neuralgia. Nonsteroidal antiinflammatory drugs and acetaminophen tend to provide only transient relief. Narcotics have minimal effect.<sup>2</sup> Ergot derivatives are controversial, with some authors claiming a short-term effect, possibly medi-

ated by constriction of the occipital artery, whereas others state that they are completely ineffective.<sup>29,35</sup> Infliximab has shown some benefit.<sup>36</sup> Local anesthetic injection alone or in conjunction with corticosteroids may provide lasting pain relief.<sup>37</sup> Botox has been shown to be effective, with a limited duration.<sup>2</sup> Neck weakness has been a complication of this in 27 percent of patients.<sup>19</sup> Ethyl alcohol

injection may improve symptoms but suffers from high recurrence rates.<sup>38</sup> Epidural corticosteroids have not been shown to be effective.<sup>39</sup>

More invasive modalities include radiofrequency lesioning of the greater occipital nerve. One case report followed a patient who demonstrated pain relief of 60 to 70 percent over 5 months. The treatment had to be repeated for continued efficacy, and long-term results are not known.<sup>13</sup> Another study of 15 patients demonstrated good relief of pain at 8.8 months after radiofrequency neurotomy of C3 to C6 dorsal rami; however, there was a tendency for the pain to recur during follow-up.<sup>40</sup> It is our observation that a number of patients who previously had radiofrequency ablation elsewhere failed decompression and subsequently required nerve excision to diminish their pain. It appears that patients who continue to have headache following the radiofrequency ablation often have increased pain, presenting similar to neuroma in continuity. We find it important to discuss this with the patient, who might then opt for nerve excision instead of decompression.

Implanted nerve stimulators have been evaluated. One study found that 16 of 30 patients (53 percent) experienced greater than 50 percent pain improvement at a mean follow-up of 35 months.<sup>6</sup> There were several complications related to the implanted device. Another study of six patients found pain relief to be greater than 50 percent in all patients at a follow-up of 3 months.<sup>7</sup> In a series of 14 patients, seven experienced greater than 50 percent pain relief at a mean follow-up of 22 months.<sup>8</sup> The expense of these systems and the hazards of implanting a foreign body should be considered against other options. In addition, the nerve stimulator treatment focus is on symptoms, whereas the peripheral nerve surgery addresses the anatomical cause of the headache—compression.

Surgical approaches have been varied. C2 and C3 nerve root decompression was reported in a single case in which the nerve was compressed by a C3 facet spur, leading to complete pain relief at 11 months' follow-up.<sup>12</sup> In this case, a proximal bony abnormality was identified by polytomography. Microsurgical C2 gangliotomy has been advocated following a series of four patients with complete pain relief after 24 months, with one patient suffering pain recurrence thereafter.<sup>19</sup> These patients experienced transient nausea and dizziness postoperatively, and one patient had a cerebrospinal fluid leak. C1 to C4 rhizotomy has been reported in 17 patients with occipital neuralgia, with 68.8 percent of patients reporting the procedure as worth-

while.<sup>11</sup> Numbness in the affected dermatomes was present after the procedure.

Subdermal denervation of the affected skin segments has been reported.<sup>14</sup> In these patients, two large scalp flaps were elevated, containing the occipitofrontalis muscle, to expose the greater and lesser occipital nerves. These were then excised and the flaps replaced. Three patients were reported to have received "satisfactory results" from this procedure. Avulsion neurectomy of the greater occipital nerve has been performed in 22 patients, with 70 percent demonstrating pain relief at 18 months.<sup>15</sup> Thirty percent of these patients experienced scalp hypersensitivity, dysesthesia, neuroma, or recurrence.

Surgical neurolysis with sectioning of the inferior oblique muscle was performed on 10 patients, with a 70 percent rate of patient satisfaction at a mean follow-up of 37 months.<sup>17</sup> In another series of 50 patients, neurolysis of the greater occipital nerve at the deep neck fascia and trapezial tunnel was found to provide short-term pain relief in 66 percent of patients. At 18-month follow-up, however, pain was found to have recurred in 46 of 50 patients.<sup>16</sup> Interestingly, 80 percent of patients did not regret the surgery and 40 percent wanted to undergo the identical operation again. These authors postulated that they may not have released the nerve deep enough, as the semispinalis muscle was not addressed. The semispinalis muscle was sectioned by Guyuron et al. in 34 patients, with 100 percent demonstrating improvement in headache pain.<sup>19</sup> Similarly, in a series of 13 patients with whiplash trauma and occipital headache, release of the nerve at the trapezial tunnel and the semispinalis resulted in 72.2 percent reporting good or excellent pain relief.<sup>18</sup> An anecdotal review of 150 patients undergoing surgery for occipital neuralgia by means of release of the trapezial tunnel found that approximately one-third of patients improved dramatically, one-third was definitely improved but still had some pain, and one-third did not benefit.<sup>4</sup>

The humoral and cellular mechanisms of headache have been well-studied, yet no consensus exists as to the exact pathway of pain generation. Interleukin-1 $\beta$  and tumor necrosis factor- $\alpha$  have been implicated as promoting hyperalgesia.<sup>2</sup> Nitric oxide may also play a role. Despite the complex molecular-biological mechanisms, it seems clear when reviewing the body of literature on this topic that there is often a peripheral trigger, such as nerve irritation, that triggers the pain cascade. Five potential sources of potential entrapment of the greater occipital nerve are observed: C2 nerve root (rarely), inferior oblique (rarely), within the



semispinalis muscle, within the trapezial tunnel (trapezius muscle/aponeurosis), and angiolymphatics (occipital artery/vein crosses the greater occipital nerve; lymph node presence, within or distal to trapezial tunnel, respectively). Nerve irritation and hyperexcitability of peripheral nociceptors may lead to central sensitization and pain evoked by nonnoxious stimuli.<sup>41</sup> The response of these types of headaches to peripheral nerve block strengthens this concept. Similarly, connections between the trigeminal nucleus and the upper four cervical roots may form the anatomical substrate for the spread of cervical pain from the neck to the head.<sup>42</sup> The proximity of the occipital artery to the greater occipital nerve has also been postulated to cause nerve compression and paroxysmal, throbbing pain.<sup>43</sup>

In our series of 206 patients, 80 percent experienced meaningful pain relief at a minimum of 12 months' follow-up. In comparison with other procedures, the greater occipital nerve is not damaged and complications are rare. When the lesser occipital nerve is excised (2 percent of cases), the resultant sensory defect is minor. These results suggest that occipital neuralgia is stimulated by peripheral nerve entrapment.

Approximately 20 percent of patients experienced less than 50 percent relief after 1 year. We suspect several reasons for treatment failure. Diagnostic error may have played a role. Many of these treatment failures had other, coexistent headache syndromes that may have come to predominate and overshadow any effect of the procedure. In some failures, abnormal branching of the greater occipital nerve was found, arousing suspicion that aberrant branches might still have been active. Atypical anatomy has been reported.<sup>44</sup> The third occipital nerve was not addressed routinely in these patients at the beginning of the study although, when identified in the operative field, it was cut and allowed to retract into muscle. Headache symptoms have been attributed to entrapment of this nerve.<sup>23</sup> We now address this intraoperatively with either decompression or excision. Although initially more attention was given to the semispinalis capitis muscle and trapezius aponeurosis, it became apparent that these two sites are among five possible sites of compression. More thorough release is now performed, including the inferior oblique, occipital artery, and lymph nodes, if present, in the trapezial tunnel. Ultimately, it is probably a combination of the above factors, in addition to a lack of regenerative potential in the long-compressed nerve, that is responsible for the treatment failures.

Interestingly, many of these patients whom we classified as treatment failures experienced some postoperative pain relief. Often, they request a second operation. In these cases, if nerve block is still effective, we offer neurectomy as a second alternative. The outcomes of this will be presented in a future work.

This procedure has limitations. Although 80.5 percent of patients benefited from surgery, only 43 percent of patients experienced complete relief. Still, these odds may be attractive to many patients, with partial abatement of symptoms allowing a more productive and enjoyable lifestyle. A detailed preoperative discussion must be undertaken to maintain reasonable expectations as part of a multidisciplinary team. We look forward to reporting these data and the results of a larger cohort in the future. The importance of multidisciplinary coordination in patient care cannot be overemphasized, including a headache-focused neurologist or anesthesia pain specialist. The administration of nerve blocks or Botox requires experience for valid, reproducible results, often used as important inclusion criteria for surgery. Lastly, it is important for the surgeon to have appropriate peripheral nerve surgery training and experience to minimize complications and optimize outcomes.

## CONCLUSIONS

The diagnosis and management of headache is a controversial topic. Of 206 patients undergoing surgical neurolysis, 80 percent had meaningful pain relief after at least 1 year of follow-up. Although many might argue that surgery is an invasive treatment for occipital neuralgia, the failure of medical management in many patients mandates exploration of other options. Surgical neurolysis provides safe, durable pain relief to a subset of patients with occipital neuralgia-related chronic migraine headaches by addressing the causative compression sites. Clearly, more work needs to be performed before a consensus is reached. However, we hope that this study, by standardizing indications and technique, confirms the importance of surgical treatment for future work and discussion on this topic.

*Ivica Ducic, M.D., Ph.D.*

Department of Plastic Surgery  
Georgetown University Hospital  
Washington, D.C. 20007  
ducici@gunet.georgetown.edu

## REFERENCES

1. Beruto LJ, Ramos MM. Decades de med y cirug pract. *Madrid* 1821;3:145-169.



2. Martelletti P, van Suijlekom H. Cervicogenic headache: Practical approaches to therapy. *CNS Drugs* 2004;18:793–805.
3. Hecht JS. Occipital nerve blocks in postconcussive headaches. *J Head Trauma Rehabil*. 2004;19:58–71.
4. Pantaloni M, Sullivan P. Relevance of the lesser occipital nerve in facial rejuvenation surgery (Discussion). *Plast Reconstr Surg*. 2000;105:2600–2603.
5. Ballasteros-Del Rio B, Ares-Luque A, Tejada-Garcia J, Muela-Molinario A. Occipital (Arnold) neuralgia secondary to greater occipital nerve schwannoma. *Headache* 2003;43:804–807.
6. Slavin KV, Colpan ME, Munawar N, Wess C, Nersesyan H. Trigeminal and occipital peripheral nerve stimulation for craniofacial pain: A single institution experience and review of the literature. *Neurosurg Focus* 2006;21:1–5.
7. Kapural L, Mekhail N, Hayek SM, Stanton-Hicks M, Malak O. Occipital nerve electric stimulation via the midline approach and subcutaneous surgical leads for treatment of severe occipital neuralgia: A pilot study. *Anesth Analg*. 2005;101:171–174.
8. Slavin KV, Nersesyan H, Wess C. Peripheral neurostimulation for treatment of intractable occipital neuralgia. *Neurosurgery* 2006;58:112–119.
9. Stechison MT, Mullin BB. Surgical treatment of greater occipital neuralgia: An appraisal of strategies. *Acta Neurochir*. 1994;131:236–240.
10. Wand MY, Levi AD. Ganglionectomy of C-2 for the treatment of medically refractory occipital neuralgia. *Neurosurg Focus* 2002;12:1–3.
11. Kapoor V, Rothfus WE, Grahovac SC, Amin Kassam SZ, Horowitz MB. Refractory occipital neuralgia: Preoperative assessment with CT-guided nerve block prior to dorsal cervical rhizotomy. *AJNR Am J Neuroradiol*. 2003;24:2105–2110.
12. Poletti CE. A proposed operation for occipital neuralgia: C-2 and C-3 root decompression. *Neurosurgery* 1983;12:221–224.
13. Navani A, Mahajan G, Kreis P, Fishman SM. A case of pulsed radiofrequency lesioning for occipital neuralgia. *Pain* 2006;7:453–456.
14. Martin BC, Fagan PJ. The surgical therapy of certain occipital headaches. *Plast Reconstr Surg*. 1964;33:266–268.
15. Sharma RR, Devadas RV, Pawar SJ, Lad SD, Mahapatra AK. Current status of peripheral neurectomy for occipital neuralgia. *Neurosurg Q*. 2005;15:232–238.
16. Bovim G, Fredriksen TA, Stolt-Nielsen A, Sjaastad O. Neurolysis of the greater occipital nerve in cervicogenic headache: A follow up study. *Headache* 1992;32:175–179.
17. Gille O, Lavignolle B, Vital JM. Surgical treatment of greater occipital neuralgia by neurolysis of the greater occipital nerve and sectioning of the inferior oblique muscle. *Spine* 2004;29:828–832.
18. Manusson T, Ragnarsson T, Bjornsson A. Occipital nerve release in patients with whiplash trauma and occipital neuralgia. *Headache* 1996;36:32–36.
19. Guyuron B, Krieglger JS, Davis J, Amini SB. Comprehensive surgical treatment of migraine headaches. *Plast Reconstr Surg*. 2005;115:1–9.
20. Rifat SF, Lombardo JA. Occipital neuralgia in a football player: A case report. *Clin J Sports Med*. 1995;5:251–253.
21. Mosser SW, Guyuron B, Janis JE, Rohrich RJ. The anatomy of the greater occipital nerve: Implications for the etiology of migraine headaches. *Plast Reconstr Surg*. 2004;113:693–697.
22. Bogduk N. The clinical anatomy of the cervical dorsal rami. *Spine* 1982;7:319–330.
23. Dash KS, Janis JE, Guyuron B. The lesser and third occipital nerves and migraine headaches. *Plast Reconstr Surg*. 2005;115:1752–1758.
24. Natsis K, Baraliakos X, Appel HJ, Tsikaras P, Gigis I, Koebke J. The course of the greater occipital nerve in the suboccipital region: A proposal for setting landmarks for local anesthesia in patients with occipital neuralgia. *Clin Anat*. 2006;19:332–336.
25. Becser N, Bovim G, Sjaastad O. Extracranial nerves in the posterior part of the head: Anatomic variations and their possible clinical significance. *Spine* 1998;23:1435–1441.
26. Weinberger LM. Cervico-occipital pain and its surgical treatment. *Am J Surg*. 1978;135:243–247.
27. Tubbs RS, Salter EG, Wellons JC, Blount JP, Oakes WJ. Landmarks for the identification of the cutaneous nerves of the occiput and nuchal regions. *Clin Anat*. 2007;20:235–238.
28. Ward JB. Greater occipital nerve block. *Semin Neurol*. 2003;23:59–61.
29. Trescot AM. Headache management in an interventional pain practice. *Pain Physician* 2000;3:197–200.
30. Rozen TD. Non-hypothalamic cluster headache: The role of the greater occipital nerve in cluster headache pathogenesis. *J Headache Pain* 2005;6:149–151.
31. Scattoni L, Di Stani F, Villani V, et al. Great occipital nerve blockade for cluster headache in the emergency department: Case report. *J Headache Pain* 2006;7:98–100.
32. Yi X, Cook AJ, Hamill-Ruth RJ, Rowlingson JC. Cervicogenic headache in patients with presumed migraine: Missed diagnosis or misdiagnosis? *J Pain* 2005;6:700–703.
33. Tancredi A, Caputi F. Greater occipital neuralgia and arthrosis of C1-2 lateral joint. *Eur J Neurol*. 2004;11:573–574.
34. Jundt JW, Mock D. Temporal arteritis with normal erythrocyte sedimentation rates presenting as occipital neuralgia. *Arthritis Rheum*. 1991;34:217–219.
35. Martelletti P. Proinflammatory pathways in cervicogenic headache. *Clin Exp Rheumatol*. 2000;18:S33–S39.
36. Martelletti P. Inflammatory mechanisms in cervicogenic headache: An integrative view. *Curr Pain Headache Rep*. 2002;6:315–319.
37. Naja ZM, El-Rajab M, Al-Tannir MA, Ziade FM, Tawfik OM. Occipital nerve blockade for cervicogenic headache: A double blind randomized clinical controlled trial. *Pain Pract*. 2006;6:89–95.
38. Koch D, Wakhloo AK. CT-guided chemical rhizotomy of the C1 root for occipital neuralgia. *Neuroradiology* 1992;34:451–452.
39. Martelletti P, Di Sabato F, Granata M, et al. Failure of long-term epidural steroid injection in cervicogenic headache. *Eur Rev Med Pharmacol Sci*. 1998;2:10–14.
40. Van Suijlekom J, Van Kleef M, Barendse G, Sluifster ME, Sjaastad O, Weber WE. Radiofrequency cervical zygapophysial joint neurotomy for cervicogenic headache: A prospective study in 15 patients. *Funct Neurol*. 1998;13:297–303.
41. Ashkenazi A. Three common neuralgias. *Postgrad Med*. 2004;116:16–32.
42. Kerr FW. Central relationships of trigeminal and cervical primary afferents in the spinal cord and medulla. *Brain Res*. 1972;43:561–572.
43. Shimizu S, Oka H, Osawa S, et al. Can proximity of the occipital artery to the greater occipital nerve act as a cause of idiopathic greater occipital neuralgia? An anatomical and histological evaluation of the artery-nerve relationship. *Plast Reconstr Surg*. 2007;119:2029–2034.
44. Madhavi C, Holla SJ. Triplication of the lesser occipital nerves. *Clin Anat*. 2004;17:667–671.
45. Bovim G, Bonamico L, Fredriksen TA, Lindboe CF, Stolt-Nielsen A, Sjaastad O. Topographic variations in the peripheral course of the greater occipital nerve: Autopsy study with clinical correlations. *Spine* 1991;16:475–478.